

## PTA and Stenting After Previous Aortoiliac Endarterectomy

A. Derom<sup>\*1</sup>, F. Vermassen<sup>2</sup> and K. Ongena<sup>1</sup>

<sup>1</sup>Department of Surgery, Hospital De Honte, Terneuzen, The Netherlands, <sup>2</sup>Department of Vascular Surgery, University Hospital Ghent, Belgium

**Objectives:** to evaluate the feasibility and long-term results of angioplasty and stenting in the treatment of restenosis following aortoiliac endarterectomy.

**Materials and Methods:** between 1991 and 1999 19 patients underwent angioplasty with selective stenting for recurrent stenosis after previous aortoiliac endarterectomy. Aortic lesions were treated five times in four patients. At the iliac level 28 lesions (25 stenosis and three occlusions) were treated in 16 patients (one patient had a stenosis at the aortic as well as iliac level). All patients were followed clinically and by ultrasound. In the second half of 1999, an angiogram or spiral CT-angiography was performed in all patients to determine long-term outcome.

**Results:** technical success was obtained in all patients and clinical success was achieved in 18 of the 19 patients. Angiographic cumulative primary patency for aortoiliac lesions was 96% at 1 year and 76% at 3 years.

**Conclusions:** angioplasty with selective stenting of recurrent aortoiliac disease after previous aortoiliac endarterectomy is feasible and safe. Long-term clinical and angiographic patency rates are in accordance with results of aortoiliac angioplasty in general.

**Key Words:** Balloon angioplasty; Stent; Aorta; Iliac artery; Recurrence; Endarterectomy.

### Introduction

Aortoiliac endarterectomy used to be the commonest form of aortoiliac revascularisation.<sup>1</sup> In 1973 Le Veen described aortoiliac disobliteration with a plaque cracker<sup>2</sup> which is an intima guillotine instrument allowing semiclosed endarterectomy. One disadvantage of aortoiliac endarterectomy is recurrence of the disease typically in the external iliac artery.<sup>1,3,4</sup> As redo surgery can be a difficult procedure,<sup>1</sup> percutaneous transluminal angioplasty (PTA) has been proposed in a limited number of reports as an alternative. However, the outcome of angioplasty in a previously endarterectomised artery remains uncertain. Moreover, all of these reports were prior to the introduction of stenting.<sup>5–9</sup>

As endarterectomy with the plaque cracker has long been the procedure of choice for aortoiliac occlusive disease in one of our institutions since its introduction by Widdershoven in Europe,<sup>10,11</sup> 283 patients have undergone this procedure between 1977 and 1996. A considerable number of patients with restenosis were

seen during recent years, 19 of which were symptomatic and treated by PTA and selective stenting. We therefore performed a study to evaluate the feasibility and the long-term results of angioplasty and stenting of the aorta and iliac arteries after previous endarterectomy.

### Material and Methods

Files of all the patients treated with angioplasty after previous aortoiliac endarterectomy were retrospectively studied. Between November 1991 and June 1999, 19 patients (12 males, seven females) underwent PTA with secondary stenting for recurrent disease in two institutions. The median age was 66 years (range 49–83 years). The median interval between endarterectomy and angioplasty was 8 years (range 1–19 years). Clinical work-up consisted of preoperative angiography in all patients and additional spiral CT scan in cases of aortic stenosis.

The clinical characteristics showed 17 patients with stage II Fontaine classification and two patients with critical ischaemia, stage III. The median preprocedural ankle-brachial index (ABI) which was determined in 17 patients, was 0.69 (range 0–0.95).

\* Please address all correspondence to: A. Derom, Department of Surgery, Hospital De Honte, Wielingenlaan 2, 4535 PA Terneuzen, The Netherlands.

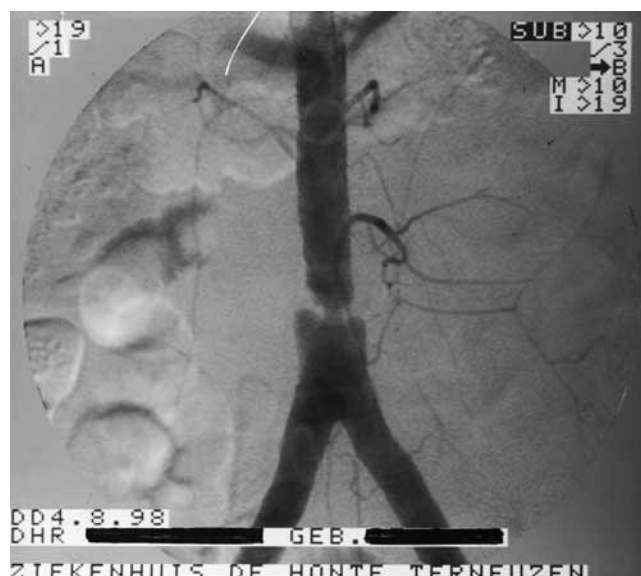

Fig. 1. Angiography illustrating a significant recurrence at the abdominal aorta 8 years after aortoiliac endarterectomy.

Table 1. Lesions' characteristics.

Site	No.	Length	Degree
<b>Stenosis</b>			
Aorta	4	0.8 (0.5–1.3)	60 (50–65)
Common iliac artery	7	1 (0.2–2)	55 (30–60)
External iliac artery	18	1 (0.5–5)	70 (30–90)
<b>Occlusion</b>			
Iliac artery	3	14 (4–14)	100

#### *Aortic lesions*

Four patients presented stenosis of the infrarenal aorta (Fig. 1). Other characteristics of the aortic lesions are given in Table 1.

Aortic angioplasty was performed five times in four patients. At the time of the first aortic PTA, large caliber stents were not yet available and a residual stenosis of 30% was left untreated. In the subsequent four procedures, stents were inserted in the abdominal aorta for residual stenosis after PTA (three Wall Stents, Boston Scientific and one Palmaz stent, Johnson and Johnson). One patient was first treated by PTA of the aorta which was followed by angioplasty of the iliac artery after 3 years.

#### *Iliac lesions*

A total of 28 lesions, 25 stenoses and three occlusions in 22 limbs were treated during 18 procedures in 16 patients. Several patients ( $n=6$ ) had both limbs affected, and some had short stenoses on both the

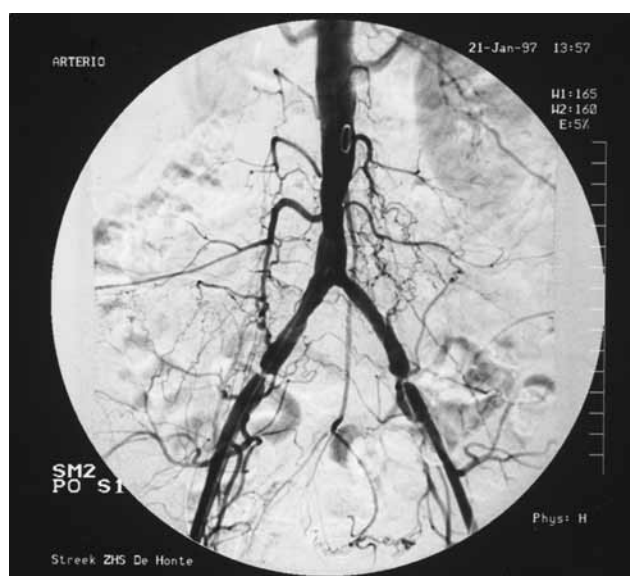

Fig. 2. Angiography revealing typical bilateral recurrent high grade stenosis at the orifice of the external iliac artery 11 years after aortoiliac endarterectomy.

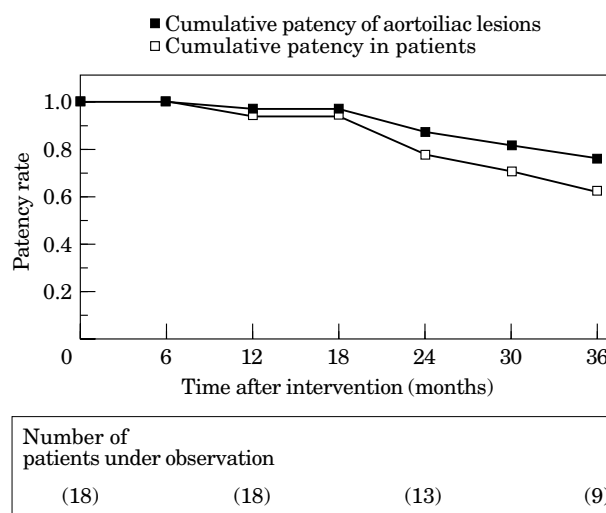


Fig. 3. Cumulative primary patency rates in aortoiliac lesions ( $n=31$ ), and in patients ( $n=15$ ).

common and external iliac artery (Fig. 2). Two patients had repeat angioplasty for new lesions due to progression of disease. The characteristics of the stenotic lesions are summarised in Table 1. Recurrence of stenosis in the external iliac artery was typically seen just distal to the orifice of the internal iliac artery. In 12 out of the 25 stenotic iliac lesions treated by PTA, angioplasty was combined with selective stenting (Wall Stent, Boston Scientific) for residual stenosis or persisting significant trans-stenotic pressure gradient. The three occlusions, discovered within weeks after their development, had catheter thrombectomy, followed by PTA with stenting.

Aspirin (80–100 mg daily) was started post-operatively on a life long regimen in most cases. Patients already on anticoagulants for cardiac disease continued their treatment.

### *Evaluation of results*

Immediate technical result was determined by on table angiography and when needed, by measuring the residual gradient. Endpoint for clinical success was defined as an improvement of at least one category in Fontaine stage II and III disease, and improvement of the ABI by more than 0.1 in the immediate post-operative period if measurements were available.

Follow-up consisted of history, clinical examination and duplex sonography. Angiography was obtained if symptoms persisted, if recurrence was suspected, or when contralateral symptoms developed. All patients, even the asymptomatic ones, were screened by angiography ( $n=13$ ), or in some cases ( $n=5$ ) by spiral CT angiography in combination with duplex sonography in the second half of 1999.

Patency was defined as normal angiographic image with less than 10% stenosis.

## **Results**

### *Immediate results*

Technical success was obtained in all cases. However, residual angiographic stenosis of 20% despite stenting was observed in two iliac arteries. Residual stenosis between 15 and 35% was observed in all cases of aortic angioplasty and stenting. Both pre and postprocedural ABI were obtained in only 15 patients. The median postprocedural ABI increased from 0.69 to 0.87 (range 0.58 to 1.18).

Clinical success and improvement of at least one category in Fontaine classification was obtained in 18 of the 19 patients. Deterioration occurred in one patient from stage II to III and later on to IV. She developed progressive gangrene of the toes which finally led to a below knee amputation after 4 months. This was probably caused by a combination of micro-embolisation and a poor outflow. She died on the 10th postoperative day of heart failure without clinical signs of restenosis of the iliac artery. In this patient, no control angiography or duplex sonography was carried out due to the short interval. No other 30-day mortality was observed.

### *Long-term results*

In total seven recurrences were observed (five external iliac stenosis, one common iliac stenosis and one iliac occlusion) after a median follow-up of 36 months (range 10–117 months). Four of seven recurrences were symptomatic and all underwent repeat PTA; in one iliac re-thrombosis preceded by catheter thrombectomy. The cumulative primary patency rate was 96% after 1 year, and 76% after 3 years (Fig. 3). The assisted primary patency rate 96% at 1 year and 76% at 3 and 4 years. Secondary patency rate was 100% at 1 year and 90% at 3 years.

## **Discussion**

Endarterectomy has been a widely accepted procedure for revascularisation of obstructive disease of the aorta and iliac arteries.<sup>1,12</sup> The introduction of aortofemoral bypass has resulted in a replacement of aortoiliac endarterectomy by prosthetic surgery in most institutions.<sup>3,13</sup> However, in one of our institutions aortoiliac endarterectomy has remained the standard procedure till the beginning of the nineties as it eliminates the risk of graft infection. A majority of the patients reported in this paper had already been included in previously published retrospective studies on the results of aortoiliac endarterectomy by Widdershoven *et al.*, as the operations had been performed in the same institution.<sup>10,11</sup> Recurrent stenosis after aortoiliac endarterectomy occurs predominantly in the external iliac artery<sup>3</sup> and is usually confined to a short segment.<sup>6</sup>

Therapeutic options consist of a repeat endarterectomy which can be hazardous.<sup>1</sup> In most cases surgeons will favour aortofemoral bypass.<sup>1,3</sup> However, PTA of recurrent disease in the iliac artery has been reported in small series,<sup>3,7–9</sup> the largest dealing with results in only six patients.<sup>5,6</sup> The only difference the author noticed, was that lesions after previous endarterectomy were harder to dilate.<sup>5,6</sup> This was confirmed in our series.

No reports were found of PTA of the aorta after previous endarterectomy, or angioplasty in combination with stenting. In carotid disease there are some preliminary data on PTA and stent placement for recurrent stenosis after endarterectomy. These show that it is feasible, safe and effective to perform, but still investigational.<sup>14</sup> Our own results indicate that all lesions, even occlusions, can be crossed with the use of hydrophilic guide wires. Most lesions were soft to dilate, but some required high pressure or the use

of high pressure balloons. If necessary, dissections were successfully treated with stents. No vessel ruptures were noticed. In most cases residual stenosis were successfully treated by stent placement. At iliac level two lesions showed a remaining moderate angiographic stenosis despite stenting. In all cases of PTA of the aorta some residual stenosis remained ranging from 15 to 35%. This was probably due to cautious approach during angioplasty to avoid rupture of a large size vessel.

Patency rate in aortic PTA after previous endarterectomy was 100% at 3 years, and is in accordance with published data of aortic stenting in general although there are only few reports of isolated infrarenal aortic PTA with stent insertion.<sup>15,16</sup>

Angiographic patency rates for aortoiliac disease at 1 and 3 years, were 96% and 76%. These results are also comparable with the results of iliac angioplasty in general. The Dutch trial concerning PTA of occlusive disease of the iliac artery with selective stenting shows 2-year clinical patency rates of 78%.<sup>17</sup> The Wallstent study shows similar results at 2 years.<sup>18</sup> In cases of long occlusions or diffuse iliac lesions, reported patency decreases significantly.<sup>19</sup> Clinical patency rate of the present study compares favourably with other reports.<sup>17,18</sup> The difference in angiographic and clinical patency rate further confirms that clinical follow-up alone is not reliable to determine the occurrence of restenosis.<sup>19</sup>

Repeat iliac PTA after previous endarterectomy is safe as it was performed without problems in three cases for recurrence. Stents were inserted on a selective basis in these cases. Follow-up in these patients has so far shown one recurrence.

### Conclusions

PTA in combination with selective stenting after previous aortoiliac endarterectomy is a feasible and safe technique. The complications compare favourably with those of redo surgery. No specific endovascular problems were noticed during the procedures apart from the need for high inflation pressures in some patients. Long-term results of secondary aortoiliac angioplasty in combination with stenting are good, and

in accordance with the results of iliac angioplasty in general. If recurrence occurs, a repeat angioplasty can be performed safely.

### References

- 1 GASPAR DJ, COHEN JL, GASPAR MR. Aortoiliac endarterectomy vs bypass graft. *Arch Surg* 1972; **105**: 898–901.
- 2 LE VEEN HH, DIAZ C, CHRISTOUDIAS G. The postendarterectomy intimal flap. *Arch Surg* 1973; **107**: 664–668.
- 3 NAYLOR AR, AH-SEE AK, ENGESET J. Aortoiliac endarterectomy: an 11-year review. *Br J Surg* 1990; **77**: 190–193.
- 4 INAHARA T. Eversion endarterectomy for aortoiliac occlusive disease a 16-year experience. *Am J Surg* 1979; **138**: 196–204.
- 5 TISNADO J, VINES FS, BARNES RW, BEACHLEY MC, CHO SR. Percutaneous transluminal angioplasty following endarterectomy. *Rad* 1984; **152**: 361–364.
- 6 TISNADO J, CHO SR, BEACHLEY MC. Percutaneous transluminal angioplasty following endarterectomy. *Crit Rev Diagn Imaging* 1988; **28**: 213–293.
- 7 BARRAL X, ESPALIEU P, BRUSQ A, HEYNEN Y, DESCOTES J. Les échecs précoces de l'endarterectomie iliaque par voie rétro-péritonéale. *Lyon Chir* 1982; **78**: 182–186.
- 8 ROBERTS B, GERTNER M, RING E. Balloon-catheter dilation as an adjunct to arterial surgery. *Arch Surg* 1981; **116**: 809–812.
- 9 BACHMAN D, CASARELLA W, SOS T. Percutaneous iliofemoral angioplasty via the contralateral femoral artery. *Radiology* 1979; **130**: 617–621.
- 10 WIDDERSHOVEN GMJ, LE VEEN H. Closed endarterectomy; preferred operation for aortoiliac occlusive disease. *Arch Surg* 1989; **124**: 986–990.
- 11 WIDDERSHOVEN GMJ, WILLEKENS FGJ, KIRK RS. Disobliteration of the aorto-iliac (-femoral) arteries with the plaque cracker, using the retroperitoneal approach. *Int Angiology* 1985; **4**: 243–248.
- 12 MELLIERE D, BLANCAS A, DESGRANGES P, BECQUEMIN JP. The underestimated advantages of iliofemoral endarterectomy. *Ann Vasc Surg* 2000; **14**: 343–349.
- 13 RUTHERFORD R. Options in the surgical management of aortoiliac occlusive disease: a changing perspective. *Cardiovasc Surg* 1999; **7**: 5–12.
- 14 LANZINO G, MERICLE R, LOPES D *et al.* Percutaneous transluminal angioplasty and stent placement for recurrent carotid artery stenosis. *J Neurosurg* 1999; **90**: 688–694.
- 15 SHEERAN S, HALLISEY M, FERGUSON D. Percutaneous transluminal stent placement in the abdominal aorta. *JVIR* 1997; **8**: 55–60.
- 16 NYMAN U, UHER P, LINDH M, LINDBLAD B, IVANCEV K. Primary stenting in infrarenal aortic occlusive disease. *Cardiovasc Intervent Radiol* 2000; **23**: 97–108.
- 17 TETTEROO E, VAN DER GRAAF Y, BOSCH JL *et al.* Randomized comparison of primary stent placement versus primary angioplasty followed by selective stent placement in patients with iliac-artery occlusive disease. *Lancet* 1998; **351**: 1153–1159.
- 18 MARTIN E, KATZEN B, BENENATI J *et al.* Multicenter trial of the wallstent in the iliac and femoral arteries. *JVIR* 1995; **6**: 843–849.
- 19 NAWAZ S, CLEVELAND T, GAINES P, BEARD J, CHAN P. Aortoiliac stenting, determinants of clinical outcome. *Eur J Vasc Endovasc Surg* 1999; **17**: 351–359.